

Case studies in novel narial anatomy: 3. Structure and function of the nasal cavity of saiga (Artiodactyla: Bovidae: *Saiga tatarica*)

Andrew B. Clifford^{1,2} and Lawrence M. Witmer^{3*}

¹ Department of Biological Sciences, Ohio University, Athens, OH 45701, U.S.A.

² Department of Ecology and Evolutionary Biology, Brown University, Providence, RI 02912, U.S.A.

³ Department of Biomedical Sciences, College of Osteopathic Medicine, Ohio University, Athens, OH 45701, U.S.A.

(Accepted 10 February 2004)

Abstract

Much of the narial anatomy of the enigmatic antelope *Saiga tatarica* has been described by previous workers. However, the anatomy of the nasal cavity and the causally associated osteological correlates of proboscis structure require closer attention, because these data are integral for both a more comprehensive understanding of saiga functional morphology and more robust reconstructions of proboscis structure in fossil taxa. Saiga and outgroup specimens were subjected to X-ray computed tomographic (CT) imaging, gross dissection and skeletonization. The nasal cavity of saiga is characterized by an enlarged nasal vestibule and basal conchal fold. Many structures (e.g. turbinates, lateral cartilages, mucosal folds, nasolacrimal duct) are retracted caudally to a small area in the caudodorsal part of the nasal cavity proper. The enlarged vestibule is associated laterally and ventrally with paired sacs. The nasal septum is largely membranous and contains a large patch of cavernous tissue that serves as a dynamic baffle modifying the flow of inspired air. Bones comprising the narial margin have modified attachment sites for buccinator group muscles and the reduced lateral cartilages. The premaxilla is greatly modified by the enlarged musculature associated with nasolabial fusion. Maintenance of the topological relationships of narial structures compared to bovid outgroups has resulted in a nasal cavity with much larger area for seromucous glands of the vestibule as well as narial musculature capable of controlling the aperture of the nasal cavity. Maxillolabial muscles and the lateralis nasi act together both to compress the nasal cavity and to control the dilation of the nostrils such that air flow through the cavity is highly modified relative to bovid outgroups. The lateral vestibular recess is an outpocketing of the nasal vestibule that produces supplementary seromucous secretions and seems to have no homologue among outgroups. The enlarged nasal vestibule, lateral vestibular recess, repositioned basal fold, and septal cavernous mass are regarded as a coordinated adaptation to dusty habitats, such that nasal air flow can be dynamically regulated allowing for collection of inspired particulates in the vestibule and thus cleansing of air destined for the lungs.

Key words: Artiodactyla, Bovidae, *Saiga*, nasal vestibule, proboscis, nasal physiology

INTRODUCTION

Saiga *Saiga tatarica* are a relatively little studied but morphologically disparate group of antelopes (Fig. 1). Bovidae (e.g. antelopes, cattle) have undergone a dramatic radiation in the past 18 million years, now encompassing 135 species (Vrba & Schaller, 2000). Previously of varying affiliation (e.g. Caprinae in Nowak, 1999), saiga are now regarded as members of Antilopinae within Bovidae (Vrba & Schaller, 2000). Saiga have been difficult to place phylogenetically because they are bizarrely apomorphic,

particularly in the head and skull as a result of their evolution of unique narial structures. Like many other antelopes, only males possess horns, but their most distinguishing characteristic, a conspicuous proboscis, is possessed by both males and females. The inflated proboscis of saiga provides a case study in the evolution of novel narial anatomy within an otherwise morphologically and phylogenetically well-resolved clade.

Saiga are a relatively young species, first occurring in middle Pleistocene deposits approximately 1 million years ago, although some authors (Heptner, Nasimovich & Bannikow, 1988) speculated that this genus may occur as far back as the late Pliocene. Only one other species of *Saiga* is currently recognized (*S. prisca*), although the Mongolian population previously received species rank

*All correspondence to: L. M. Witmer.

E-mail: witmer@exchange.oucom.ohiou.edu

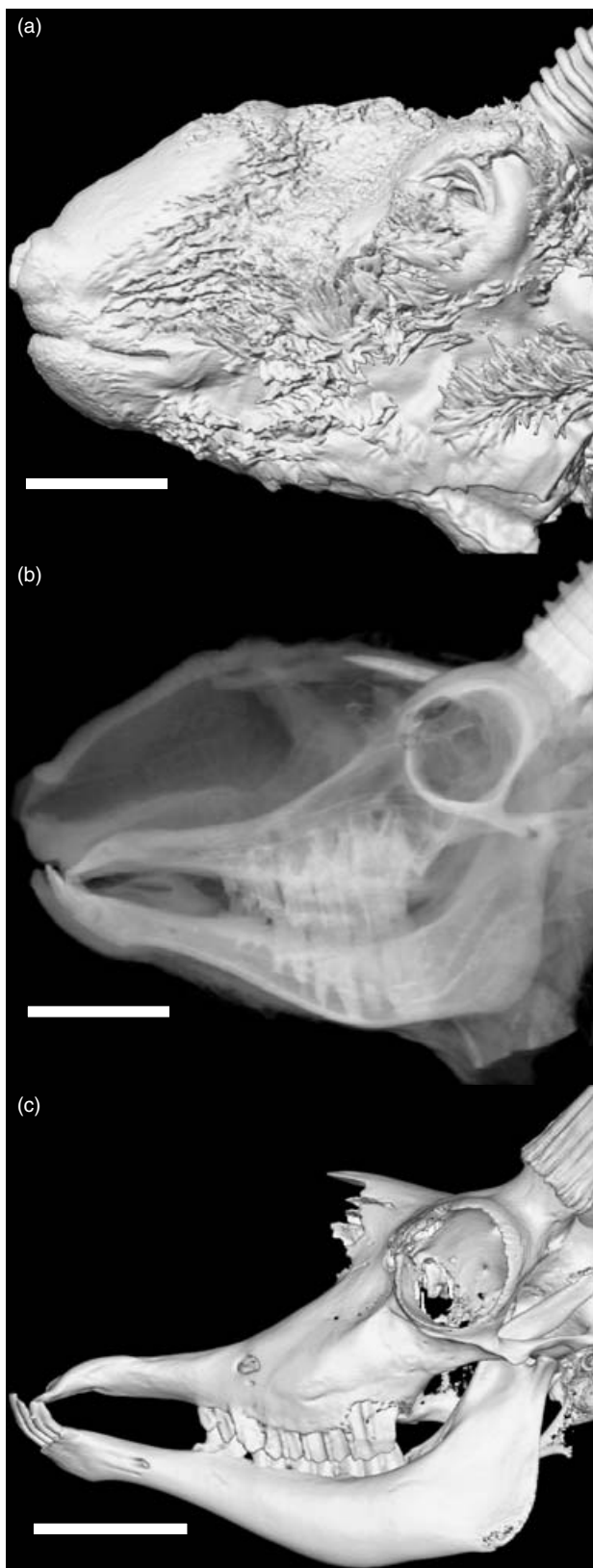

Fig. 1. The head of *Saiga tatarica* in left lateral view, based on 3D reconstructions of CT scans of AMNH 202492: (a) isosurface of the intact head; (b) voxel reconstruction of intact head to simulate a lateral radiograph; (c) skull isosurface. Scale bars = 5 cm.

(Heptner *et al.*, 1988). Generally, fossil saiga are virtually identical to Recent forms, differing mostly in geographical range (Sokolov, 1974). Occurring now only in open, dusty, arid grasslands of central Asia, their range once extended from the British Isles to eastern Alaska (Frick, 1937).

The inflated narial apparatus in saiga has been studied to various extents by previous workers. Murie (1870) gave an extensive account of the anatomy of the whole animal, discussing much of the musculature and innervation of the proboscis, as well as some aspects of the nasal cartilages and skull, attributing the peculiar nose to an increase in tactile sensation (Murie, 1870). Boas & Pauli (1908) figured the skull but offered few other anatomical details. Jacobi (1921) provided a diagram of the skull and nasal cartilages (seemingly based largely on Murie, 1870) to describe the apparent convergence between many phylogenetically disparate proboscis-bearing mammals. Lodyshenskaya (1952) described the complex narial musculature and nasal cartilages, adding developmental and histological components. More recently, Frey & Hofmann (1995, 1997) conducted a series of morphological studies of the proboscis in saiga, focusing on the skull, glands, musculature, and anatomical differentiation from another proboscis-bearing bovid, Guenther's dikdik *Madoqua guentheri*. All of these studies differ from each other in focus, completeness and terminology.

This study has two major aims. The first is to highlight functional aspects of the transformation of the nasal cavity of saiga, based on cross-sectional anatomy and dissection. The second is to detail the causally associated bony modifications of the skull resulting from the evolution of a proboscideal nose in saiga. The anatomical configuration of internal narial structures remains largely undescribed. Previous work has either omitted apomorphies occurring inside the nose or has only briefly described certain features. In addition, the osteological correlates of soft tissues comprising the nose in saiga remain undescribed. The present study is part of a larger effort attempting to describe the functional anatomy of apomorphic narial structures in extant amniotes (Witmer, Sampson & Solounias, 1999; Clifford & Witmer, 2001, 2002*a,b*, 2004; Witmer, 2001*a,b*). The project as a whole seeks to explain how anatomical specialization results in causally associated bony features in proboscis-bearing taxa. A goal is to assess the presence or absence of novel soft-tissue structures in extinct taxa by appeal to osteological correlates of these soft tissues found in extant taxa (Witmer, 1995). Previous work has concentrated largely on muscular, cartilaginous, nervous, and vascular specializations in saiga without integrating many internal changes in the nasal cavity into potential causally associated features of the skull, and this study seeks to fill that gap.

MATERIALS AND METHODS

A skull (AMNH 119649) and an intact head (AMNH 202492) were the primary source of data for this study.

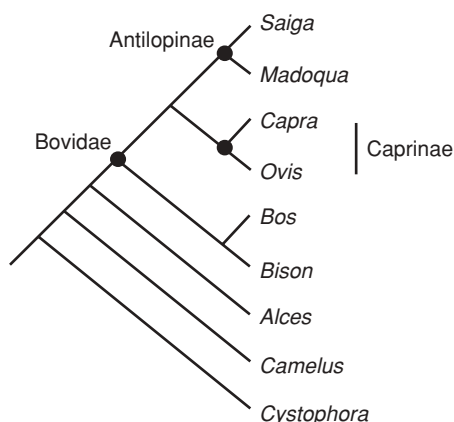


Fig. 2. Phylogenetic relationships of taxa and clades referred to in this study. Topology based on Hassanin & Douzery (2003).

The intact head was a zoo specimen later preserved as a fluid specimen. Before dissection, the intact specimen was subjected twice to X-ray computed tomography (CT) at O'Bleness Memorial Hospital in Athens, Ohio, using a GE HiSpeed Fx-i Helical CT Scanner. The first scan was set at 140.0 kV, 170.0 mA, 5.0 mm slice thickness, using both standard and bone algorithms. The second scan was set at 140.0 kV, 160.0 mA, 2.0 mm slice thickness, using a bone algorithm. The CT data were exported in DICOM format using eFilm (v. 1.5.3, Merge eFilm, Toronto). Analysis and postprocessing used the software packages eFilm (v. 1.8.3) and Amira (v. 3.0, TGS, Inc., San Diego). Both sectional anatomy and 3D reconstructions derived from the slice data were analysed. Study of the head also included gross dissection and sagittal sectioning with a band saw. Following sagittal sectioning, the right side was CT scanned a third time (120.0 kV, 130.0 mA, 1.0 mm slice thickness, bone algorithm). Dissections were recorded with digital photography. Figures 1, 3, 5 & 6 were produced from reconstructed CT data using Amira.

To determine the anatomy of bovid outgroups (Fig. 2), skulls of *Madoqua saltiana* (Salt's dikdik; OUV 9575), *Ovis aries* (domestic sheep; OUV 9704), *Bos taurus* (domestic ox; OUV 9473, 9474, 9475, 9476, 9477, 9478, 9479, 9480, 9481, 9482, 9547, 9548, 9558), and *Bison bison* (American bison; OUV 9484, 9489, 9557), in addition to intact heads of *Capra hircus* (domestic goat; OUV 9744, 9746), were examined before dissection of the saiga. One *Capra* (OUV 9744) was injected in both carotid arteries with radio-opaque barium/latex (per Sedlmayr & Witmer, 2002), CT scanned (120.0 kV, 100.0 mA, 1.0 mm slice thickness, bone algorithm), and analysed as above. Additionally, previous research (see above), veterinary texts (Nickel, Schummer, Seiferle & Sack, 1973; Getty, 1975; Nickel, Schummer, Seiferle, Frewein *et al.*, 1986; Schaller, 1992), and *Nomina Anatomica Veterinaria* (NAV, 1994) were consulted to standardize terminology and homologize the narial structures of saiga.

RESULTS

Overview of nasal cavity

The most remarkable attribute of the nasal cavity of saiga is, relative to outgroups, the enormous nasal vestibule, the expansion of which has led to a major reorganization of the entire nose. For example, the nasal passage can be divided into two distinct regions (Fig. 3). The first region is a wide-open chamber comprised of the expanded nasal vestibule at the rostral end of the passage, the central space in the passage, and the nasopharyngeal duct (ductus nasopharyngeus; Figs 3a & 4i; *dnp*). The second region is the restricted, caudodorsal portion of the nasal cavity, which is tightly packed with conchae. At the caudal end of the nasal vestibule, there is a blind recess or sac which opens rostrally and is lined with hair and vestibular mucosa ('nasal sac' of Murie, 1870). There is another recess whose dorsal wall forms the floor of the nasal vestibule ('shelf' of Murie, 1870). The mucosa in this ventral recess is much like the mucosa of the nasal vestibule, but it is not lined with hair. The nostrils are the narrowest portion of the nasal passage. The following description emphasizes the various parts of the nasal cavity and mucosal structure in saiga. Muscles and cartilages have been described elsewhere (Murie, 1870; Lodyshenskaya, 1952; Frey & Hofmann, 1995, 1997). Standard veterinary nomenclature will be applied to anatomical structures.

Nasal vestibule

Vestibulum nasi (Figs 3a & 4b-d; *vn*). The nasal vestibule extends immediately caudal to the nostrils. In saiga, the nostrils are separated only by a thin continuation of the nasal septum, rather than by a rhinarium (planum nasi), which is well-developed in other bovids but not in saiga (Murie, 1870). The nostrils are oval and set close to the mouth. In the specimen described here, the nostrils did not overhang the mouth, although other workers have described a more pendulous proboscis (Murie, 1870; Sokolov, 1974; Heptner *et al.*, 1988). The nostrils are tightly bound in position by musculature extending from the dorsolateral surface of the premaxilla (incisive bone) and winding around the nostril. The mucosa of the nasal vestibule is thick and fur-lined, although the hairs in the vestibule are much shorter and more sparsely distributed than the hairs covering the head. From a gross perspective, small seromucous glands occur throughout the vestibule on its dorsal, lateral and ventral walls. These glands occur in vestibular mucosa that has undergone significant fibrofatty elaboration compared to ruminant outgroups. The vestibule extends caudally to the crescentic rostral edge of the basal fold (plica basalis) at the limen nasi. At the limen, the mucosa changes to respiratory mucosa, as is typical for mammals generally. Lateral to the limen is the ostium of the lateral recess, and medial to it is the ostium of the nasolacrimal duct.

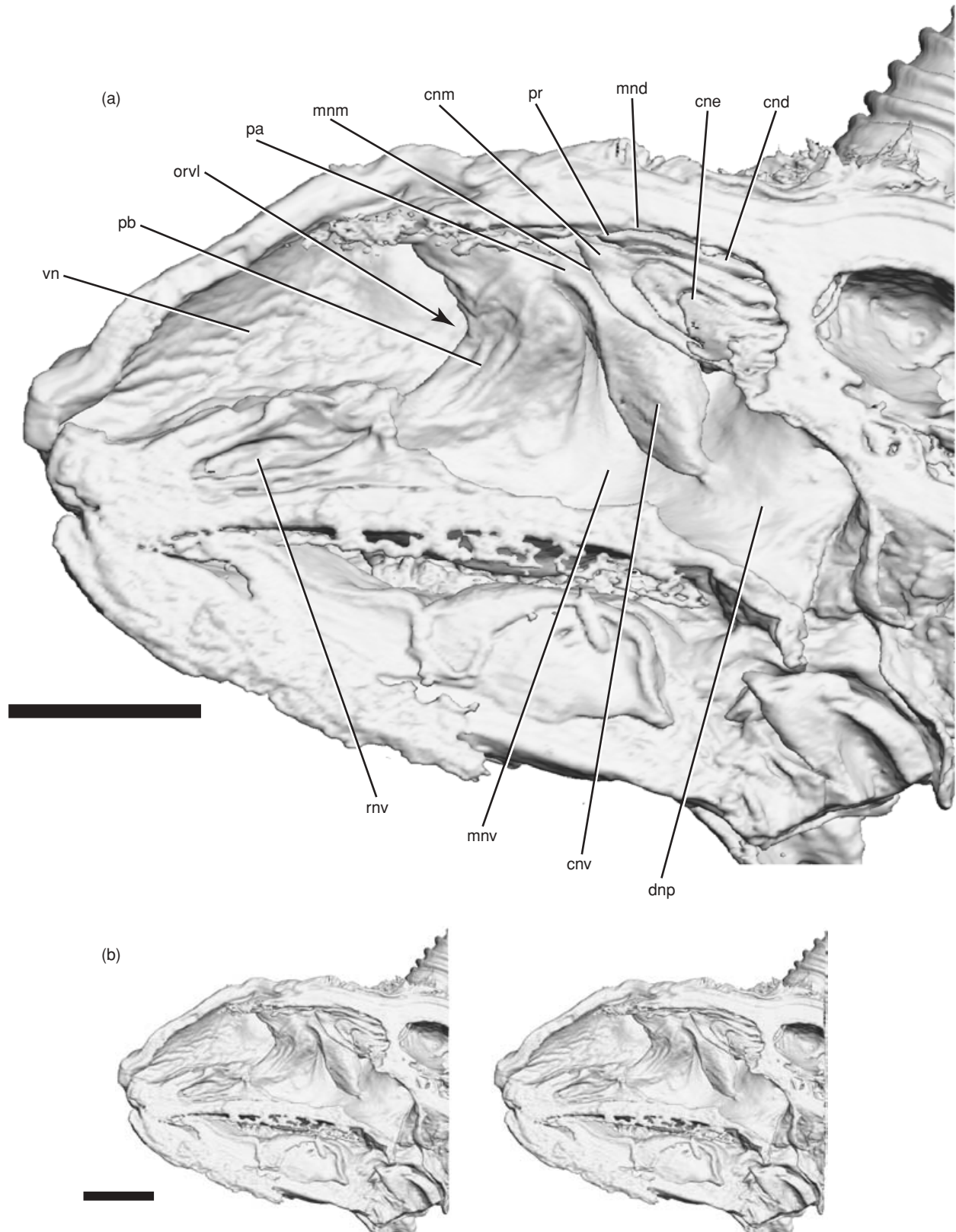


Fig. 3. Medial view of sagittally sectioned head of *Saiga tatarica*: (a) labelled drawing of isosurface of AMNH 202492 based on 3D reconstructions of CT scans; (b) stereopairs of specimen in (a). Scale bars = 5 cm. Abbreviations as in Table 1.

Recessus vestibularis lateralis (Figs 3a & 4f; *rvl*). The lateral recess of the nasal vestibule is roughly oval coronally and semicircular in sagittal section. Its opening into

the main nasal vestibular chamber occurs in the middle of the rostralateral edge of the basal fold about halfway along the rostrocaudal extent of the entire nasal passage.

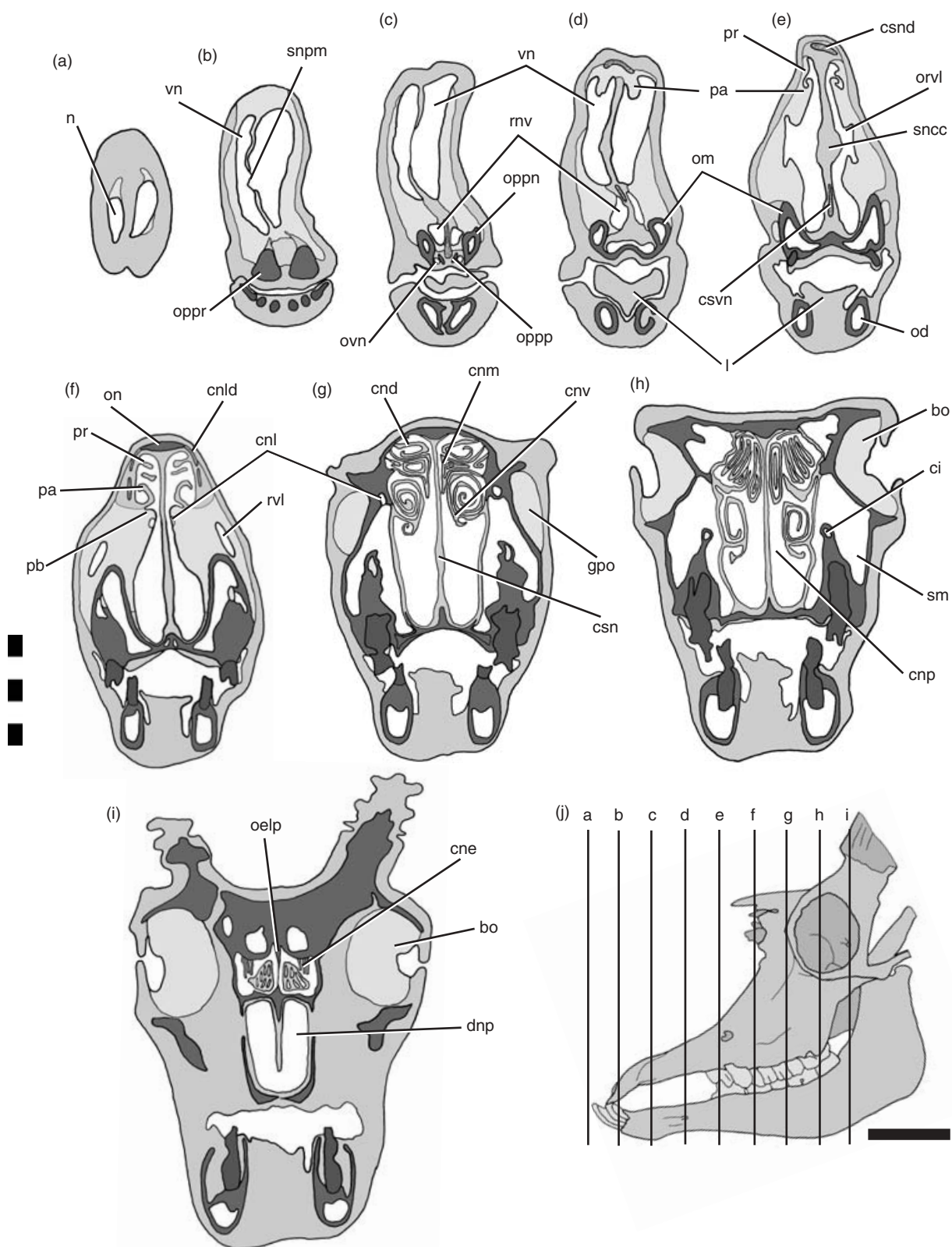


Fig. 4. Drawings of selected computerized tomographic slices of the head of *Saiga tatarica* (AMNH 202492) showing narial structures in successive transverse sections (a–i); (j) skull in left lateral view to show the rostrocaudal levels of sections depicted in (a–i). Scale bars = 5 cm. Abbreviations as in Table 1.

Table 1. List of abbreviations used in figures. *, terms named in this study and not found in NAV (1994)

bo	Bulbus oculi (Fig. 4h & i)
ci	Canalis infraorbitalis (Figs 4h & 6a)
cnd	Concha nasalis dorsalis (Figs 3a & 4g)
cne	Conchae nasalis ethmoidales (Figs 3a & 4i)
cnl	Canalis nasolacrimalis (Fig. 4f & g)
cnld	Cartilago nasi lateralis dorsalis (Fig. 4f)
cnm	Concha nasalis media (Figs 3a & 4g)
cnp	Cavum nasi proprium (Fig. 4h)
cnv	Concha nasalis ventralis (Figs 3a & 4g)
csn	Cartilago septi nasi (Fig. 4g)
csnd	Cartilago septi nasi, processus dorsalis (Fig. 4e)
csnv	Cartilago septi nasi, processus ventralis (Fig. 4e)
dnp	Ductus nasopharyngeus (Figs 3a & 4i)
gpo	Glandula preorbitalis (Fig. 4g)
l	Lingua (Fig. 4d & e)
mnd	Meatus nasi dorsalis (Fig. 3a)
mm	Meatus nasi medius (Fig. 3a)
mnv	Meatus nasi ventralis (Fig. 3a)
n	Naris (Fig. 4a)
ocnv	Os conchae nasalis ventralis (maxilloturbinate) (Figs 5a & 6a)
od	Os dentale (Mandibula) (Fig. 4a)
oee	Os ethmoidale, ethmoturbinates (Fig. 6a)
oelc	Os ethmoidale, lamina cribrosa (Fig. 6a)
oelp	Os ethmoidale, lamina perpendicularis (Fig. 6a)
oent	Os ethmoidale, nasoturbinates (Figs 5a & 6a)
olpn	Os lacrimale, processus nasolacrimalis (Fig. 5a)
olt	Os lacrimale, tuberculum (Fig. 5a)
om	Os maxillare (maxilla) (Fig. 6a)
omcf	Os maxillare, crista facialis (Fig. 5a)
omfi	Os maxillare, foramen infraorbitale (Fig. 5a)
omti	Os maxillare, tuberculum infraorbitale (Fig. 5a)
on	Os nasale (Figs 4f, 5a & 6a)
onp	Os nasale, processus (Fig. 5a)
oppn	Os premaxillare (os incisivum), processus nasalis (Figs 4c, 5a & 6a)
oppp	Os premaxillare (os incisivum), processus palatinus (Figs 4c & 6a)
oppr	Os premaxillare (os incisivum), processus rostralis (Figs 4b, 5a & 6a)
orvl	Ostium recessus vestibularis lateralis (Figs 3a & 4e)*
ovn	Organum vomeronasale (Fig. 4c)
pa	Plica alaris (Figs 3a & 4d-f)
pb	Plica basalis (Figs 3a & 4f)
pr	Plica recta (Figs 3a, 4e & f)
rvn	Recessus nasi ventralis (Figs 3a, 4c & d)*
rvi	Recessus vestibularis lateralis (Fig. 4f)*
sm	Sinus maxillaris (Figs 4h & 6a)
snc	Septum nasi, corpus cavernosum (Fig. 4e)*
snp	Septum nasi, pars membranacea (Fig. 4b)
vn	Vestibulum nasi (Figs 3a & 4b)

The sac then extends caudolaterally, somewhat mediolaterally compressed, over the edge of the nasomaxillary incisure. Its caudalmost extent is lateral to the maxilla, underlying musculature (e.g. m. levator labii superioris and m. caninus) responsible for compressing the proboscis (Murie, 1870) and situated just rostral to the preorbital gland (Fig. 4g; *gpo*; Frey & Hofmann, 1997). The mucosa lining the interior of the lateral recess is nearly identical to that in other parts of the nasal vestibule, even to the extent that it contains small hairs and minute glandular

ostia. Its mucosa is thickened by fibrofatty elaboration, as elsewhere in the nasal vestibule. No muscles, cartilages, or bones could be found associated with the lateral recess; it occurs simply as an outpocketing of the nasal vestibule.

Canalis nasolacrimalis (Fig. 4f & g; *cnl*). The nasolacrimal canal is the primary connection between the nasal cavity and the orbit. Generally in bovids, this canal opens near the limen nasi, at the juncture of the vestibular mucosa and the respiratory mucosa of the nasal cavity proper (Nickel, Schummer, Seiferle & Sack, 1973). In saiga, this delineation can be clearly seen on the basal fold. As the nasolacrimal canal exits the lacrimal bone to enter the nasal vestibule, it next enters a space within the basal fold between the ventral portion of the dorsal lateral cartilage (Fig. 4f; *cnld*) and the ventral lateral cartilage ('sesamoid cartilage' of Murie, 1870). The mucosal ostium of the nasolacrimal canal occurs relatively far dorsal within the nasal vestibule, just medial to the rostral lip of the crescent of the basal fold.

Main nasal cavity

Cavum nasi proprium. The nasal cavity proper extends from the limen nasi caudally to the nasopharyngeal duct. The mucosa in the nasal cavity proper is differentiated into a respiratory region (regio respiratoria) on the ventral concha and rostral parts of the ethmoid conchae and a pigmented olfactory region (regio olfactoria) covering the caudal portion of the ethmoid conchae. The turbinate-supported nasal conchae and the meatuses between them are displaced caudodorsally in the nasal cavity. In outgroups, the nasal cavity proper takes up the vast majority of the nasal passage (Nickel, Schummer, Seiferle & Sack, 1973), whereas in saiga it is much smaller and is telescoped caudally by the expanded vestibule. The conchae are somewhat closed off by the basal fold, and the mucosal folds extending rostrally from the conchae are generally reduced.

Plica basalis (Figs 3a & 4f; *pb*). The basal fold is the ventralmost mucosal fold of the main nasal cavity. This fold in saiga extends from the rostralmost extension of the turbinate-supported portion of the ventral concha ventrally to the floor of the nasal vestibule. The thickened, fatty mucosa of the basal fold is covered with minute folds. Its rostral margin is crescentic. The space rostral to the basal fold is the nasal vestibule, the major space of the nasal passage in saiga. The space caudal to the basal fold is much smaller, forming the ventral meatus (meatus nasi ventralis; Fig. 3a; *mnv*). Just rostral to the crescent of the basal fold is the ostium of the lateral recess of the nasal vestibule. Within the fibrofatty basal fold, the major lateral cartilages of saiga can be found. The dorsal lateral nasal cartilage (cartilago nasalis lateralis dorsalis; 'lower lateral cartilage' and 'upper lateral cartilage' of Murie, 1870) is suspended within the rostral crescent of the basal fold. A smaller flange of cartilage attaching to the ventralmost edge of the dorsal lateral cartilage (cartilago

nasalis lateralis ventralis; 'sesamoid cartilage' of Murie, 1870) extends caudoventrally to attach on the lacrimal bone. These two cartilaginous structures frame the rostral ostium of the nasolacrimal canal, which opens onto the basal fold near the edge of the rostral crescent.

The dorsal lateral nasal cartilage is figured both in Murie (1870) and in Lodysenskaya (1952), and the two major paired lateral components of the lateral cartilages are given different anatomical names. Some mammals share this feature (having two cartilaginous processes extending ventrolaterally along the lateral wall of the nasal cavity), and the two cartilaginous laminae are referred as dorsal lateral cartilages (Nickel, Schummer, Seiferle & Sack, 1973). Thus, the two paired laminae of lateral cartilages in saiga are most likely homologous to, and properly named, dorsal lateral nasal cartilages. Attaching to the rostral portion of the dorsal lateral nasal cartilage and ventral portion of the nasomaxillary incisure, many mammals also possess a ventral lateral nasal cartilage. Murie (1870) identified a cartilaginous process extending away from the caudoventral portion of the rostral lamina of the dorsal lateral cartilage, naming it the sesamoid cartilage. In all other mammals, the cartilage attaching to the ventral portion of the nasomaxillary fissure along the lateral wall of the nasal cavity is termed ventral lateral nasal cartilage (Nickel, Schummer, Seiferle & Sack, 1973).

Concha nasalis ventralis (Figs 3a & 4g; *cnv*). The ventral nasal concha is the largest of the conchae within the nasal cavity. It is double-scrolled (characteristic of artiodactyls) and supported by the bony maxilloturbinate (os conchae nasalis ventralis; Figs 5a & 6a; *ocnv*). The dorsal scroll makes at least three complete turns, whereas the ventral scroll completes one and a half. Also characteristic of other artiodactyls, the ventral concha is widest halfway along the maxilloturbinate. The ventral concha is covered exclusively by respiratory mucosa. The ventral concha is strongly angled dorsally, becoming almost vertical, which is in marked contrast to other artiodactyls, in which it is basically horizontal.

Plica alaris (Figs 3a & 4d-f; *pa*). The alar fold in saiga is relatively very short compared to most other ruminants. This mucosal fold is the direct rostral continuation of the ventral nasal concha, and it ends rostrally just beyond the rostral edge of the basal fold. Caudally, the alar fold retains a partial scroll of the ventral concha which curls first dorsally and then ventrolaterally, making a nearly complete turn. As the fold courses laterally along the lateral wall of the nasal cavity, it becomes less scrolled. Near the rostral termination of the straight fold (*plica recta*), the attachment of the alar fold migrates dorsally along the wall of the nasal cavity. This migration continues dorsally and medially, and the alar fold ultimately terminates on the nasal septum just inside the caudal end of the nasal vestibule and dorsal to the ostia of the lateral recess and nasolacrimal canal. The mucosa of the alar fold is thick and fatty, as it is in much of the vestibule, but as the fold travels onto the nasal septum, there is a collection of cavernous tissue deep to the mucosa.

Concha nasalis dorsalis (Figs 3a & 4g; *cnd*). Dorsally, the dorsal nasal concha, supported by the nasoturbinates (Figs 5a & 6a; *oen*; endoturbinat I of Paulli, 1908), courses directly rostrally from the cribriform plate just ventral to the roof of the nasal cavity. The mucosa of the dorsal concha is respiratory rostrally and olfactory caudally. This concha is not inclined relative to outgroups, but its rostral extent is shortened in saiga. The dorsal concha makes a complete scroll before unwinding to continue as the straight fold.

Plica recta (Figs 3a & 4e-f; *pr*). The straight fold is the dorsalmost mucosal fold of the nasal cavity, and is the direct rostral continuation of the dorsal nasal concha. The straight fold travels from the end of the dorsal concha to just caudal to the point where the alar fold begins its rotation on the lateral wall of the nasal cavity. The fold is very small, and there seem to be no glandular orifices associated with lateral nasal glands as in other ruminants (Nickel, Schummer, Seiferle & Sack, 1973), and no such gland was discovered despite careful dissection. Immediately lateral to the straight fold are the flattened laminae of the dorsal lateral nasal cartilage. Between these two laminae lateral to the straight fold, there is a sheet of dense connective (non-cartilaginous) tissue commencing at the apex of and partially overlying the dorsal lateral cartilage. This plate was described by Murie (1870), and its function remains unknown. The straight fold does not undergo any rotation akin to that of the alar fold. The mucosa of the straight fold is covered in much thinner mucosa characteristic of the respiratory mucosa of the nasal cavity proper.

Concha nasalis media (Figs 3a & 4g; *cnm*). The middle nasal concha extends rostrally from the cribriform plate between the dorsal and ventral nasal conchae. The middle concha is roughly triangular in shape, with its base at the cribriform plate (Fig. 6a; *oelc*) and its apex at the level of the end of the nasoturbinates. There are no mucosal folds associated with the middle concha. As in the dorsal concha, the mucosa of the middle concha is olfactory near its attachment to the cribriform plate. Surrounding the middle concha dorsally, there are several smaller ethmoid conchae (Figs 3a & 4i; *cne*) that also are lined with respiratory and olfactory mucosa. The conchae associated with the ethmoid bone do not undergo significant rotation like that in the ventral concha.

Nasal meatuses. The air spaces between the conchae are also modified in saiga relative to their artiodactyl outgroups. The ventral nasal meatus is the largest space in the nasal cavity proper of saiga. Below the ventral concha, the ventral meatus (meatus nasi ventralis) occupies almost the entire dorsoventral extent of the nasal cavity proper, owing to the inclination of the ventral concha. Its narrowest point occurs at the termination of the ventral concha, where the nasopharyngeal duct meets the nasal cavity proper. The air space dorsal to the ventral concha and ventral to the middle concha is the middle meatus (meatus nasi medius; Fig. 3a; *mm*). This space is restricted rostrally and open caudally, resulting from the

rotation of the ventral concha. Farthest rostrally, the dorsal nasal meatus (meatus nasi dorsalis; Fig. 3a; *mnd*) occupies the space between the dorsal wall of the nasal cavity and the dorsal nasal concha. This is the smallest space in the nasal cavity. Unlike in other bovids, this space does not broadly communicate rostrally with other air spaces in the cavity due to the rotation of the alar fold. Traversing between the nasal septum and the conchae within the nasal cavity proper, the common meatus (meatus nasi communis) connects the dorsal, middle and ventral meatuses. The common meatus remains laterally compressed, as structures extending out from the lateral wall of the nasal cavity approximate the nasal septum.

Recessus nasi ventralis (Figs 3a & 4c-d; *rnv*). The ventral recess in the nasal cavity is the ventralmost space in the cavity. The ostium of the ventral recess opens caudally into the ventral nasal meatus just caudal to the ventral termination of the basal fold. Directly ventrally, the ventral recess is bounded by the palatine processes of the premaxilla and maxilla. The recess is bounded laterally by the maxilla and medially by the nasal septum. Along its ventromedial margin, the recess lies directly next to the vomeronasal organ. The dorsal relations of the ventral recess are mostly muscular. A series of strong muscle fibers from *m. incisivus superior* extends from the rostral surface of the premaxilla to insert on the nasal vestibule near the ventral termination of the basal fold.

Organum vomeronasale (Fig. 4c; *ovn*). The vomeronasal organ of saiga courses along the ventral and lateral surface of the nasal septum. Caudally, the organ is associated with the opening of the ventral recess of the nasal cavity and the ventral attachment of the basal fold. The vomer and the palatine process of the premaxilla separate the vomeronasal organ from the ventral process of the septal cartilage. The organ itself is contained in an envelope of cartilage (cartilago vomeronasale) that extends from about the rostral extent of the palatine bone to the incisive duct. The organ communicates with the oral cavity through the incisive duct, ultimately opening on either side of the incisive papilla. The lumen of the vomeronasal organ remains patent for much of its length, clearly separated from the ventral recess of the cavity in cross-section (Fig. 4c).

Nasal septum

The nasal septum (septum nasi) in saiga consists of three major parts, from caudal to rostral: (1) lamina perpendicularis of the ethmoid (Fig. 4i; *oelp*); (2) cartilago septi nasi (Fig. 4g; *csn*); (3) pars membranacea (Fig. 4b; *snpm*). The perpendicular plate of the ethmoid lies between contralateral ethmoturbinates. It is much reduced in saiga, accompanying the caudodorsal retraction of the ethmoturbinates. Rostral to the bony portion of the nasal septum is the cartilaginous portion. The middle portion of the septal cartilage in saiga is emarginated such that its rostral edge is roughly crescentic. The ventral prong of

the septal cartilage (Fig. 4e; *csnv*) divides the contralateral ventral recesses. Near the termination of the ventral prong of the septal cartilage, the palatine processes of the premaxillae widen along their dorsal surfaces to accept a widened bulb of cartilage lying just caudal to the nostrils. The dorsal prong of the septal cartilage (Fig. 4e; *csnd*) travels rostrally to the rostral termination of the basal fold. Farther rostrally, this prong is continued by a fibrous cord (Murie, 1870), although this could not be directly verified in the specimen described here.

Between the dorsal and ventral processes of the septal cartilage, the septum is membranous. The membranous portion of the septum extends from the rostral extent of the cartilaginous septum to the opening of the fleshy nostrils. The mucosa of the septum is considerably thinner than on the lateral walls of the vestibule, as it is not as invested with fibrofatty tissue or seromucous glands. The membranous portion of the septum is fairly uniformly thin, with the exception of a collection of cavernous tissue located directly opposite the ostium of the lateral recess (Fig. 4e *sncc*). This cavernous tissue mass is placed near the rostralmost extent of the cartilaginous septum almost exactly halfway dorsoventrally and rostrocaudally in the nasal cavity. The cavernous tissue is unique among artiodactyls studied here in that it occurs entirely within the membranous portion of the nasal septum. The mass is more or less spherical and continuous between the two sides of the nasal vestibule.

Osteological correlates of the proboscis in saiga

Os nasale (Figs 4f, 5a & 6a; *on*). As in many other proboscis-bearing mammals, the nasal bones are caudally retracted in saiga. The frontonasal suture is closed in adults (frontonasal bone; Frey & Hofmann, 1995, 1997). The nasal cartilages modify the nasal bones by leaving a rugose surface where they attach. The rostral, triangular process of the nasal bone, together with its contralateral process, supports the dorsalmost portions of the septal cartilages and the dorsal lateral nasal cartilage. Laterally, where the nasal bone contacts the lacrimal bone, there is a shallow invagination of the bony narial margin that is smoother than the medial processes. Ventral to this margin, the nasal bone sends a short process along the nasolacrimal suture (Fig. 5a; *onp*), and this process is again rugose. The dorsal lateral nasal cartilage additionally attaches on this process. Retraction of the nasal cartilages has led to the presence of attachment sites on the nasal bones.

Os lacrimale. The lacrimal bone of saiga is unique among ungulates in separating the nasal bone from the maxilla (Murie, 1870). Near the nasolacrimal suture, the lacrimal is roughened for attachment of dorsal lateral cartilages. Dorsal to the lacrimal fossa, there is a shallow but wide tubercle (Murie, 1870) that serves as the attachment of malaris, a fan-like muscle extending along the preorbital region. Along the bony narial margin, the lacrimal bone sends out two processes, one dorsal and one ventral to the bony nasal ostium of the nasolacrimal

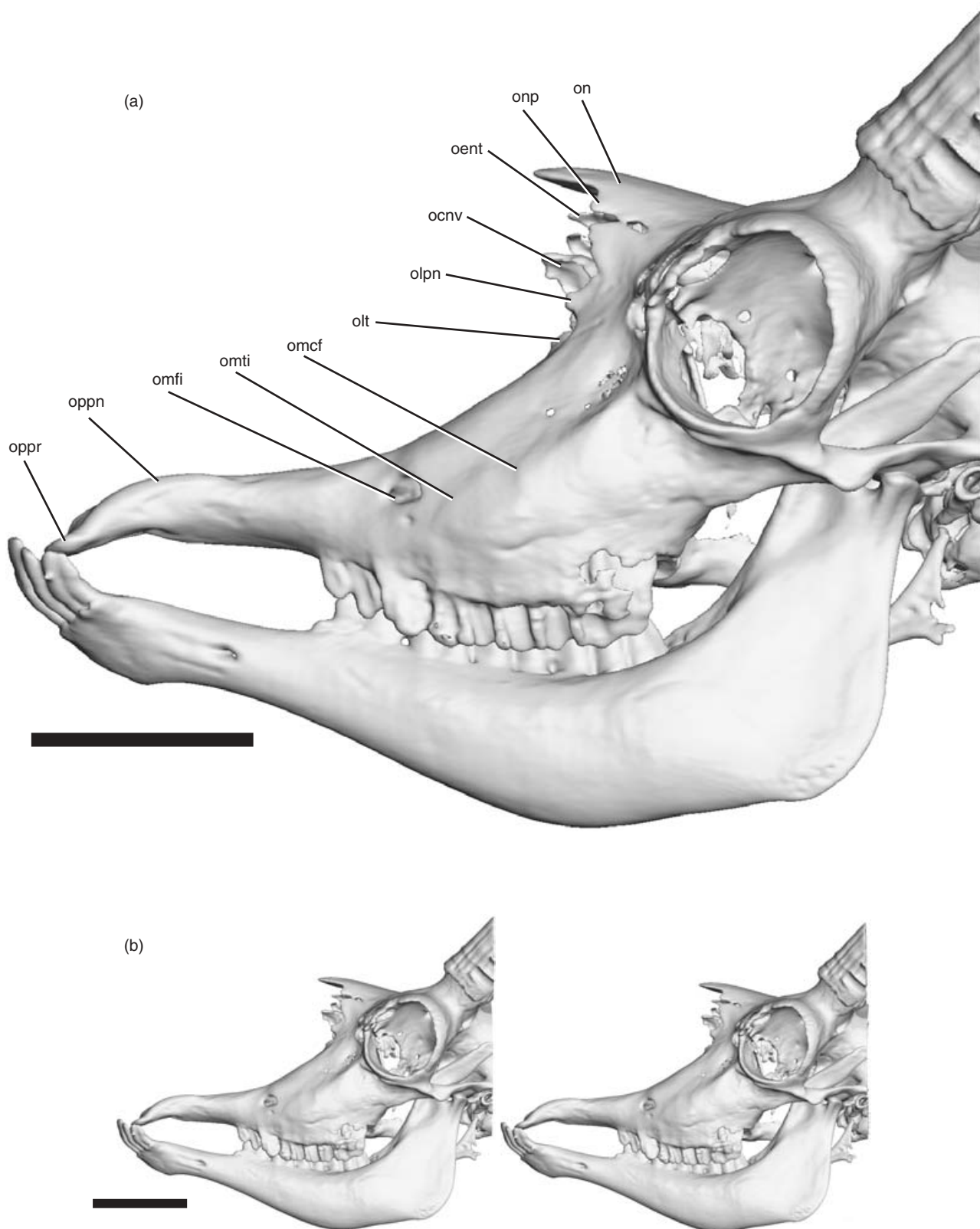


Fig. 5. Left lateral view of skull of *Saiga tatarica*; (a) labelled drawing of isosurface of AMNH 202492 based on 3D reconstructions of CT scans; (b) stereopairs of specimen in (a). Scale bars = 5 cm. Abbreviations as in Table 1.

canal. The dorsal process (Fig. 5a; *olpn*) does not attach to any muscular or cartilaginous structures but rather apparently serves as a dorsal support for the nasolacrimal

canal, as its rostral edge abuts the curved process of the ventral lateral nasal cartilage. This process results from the caudal relocation of the nasolacrimal canal. Ventral

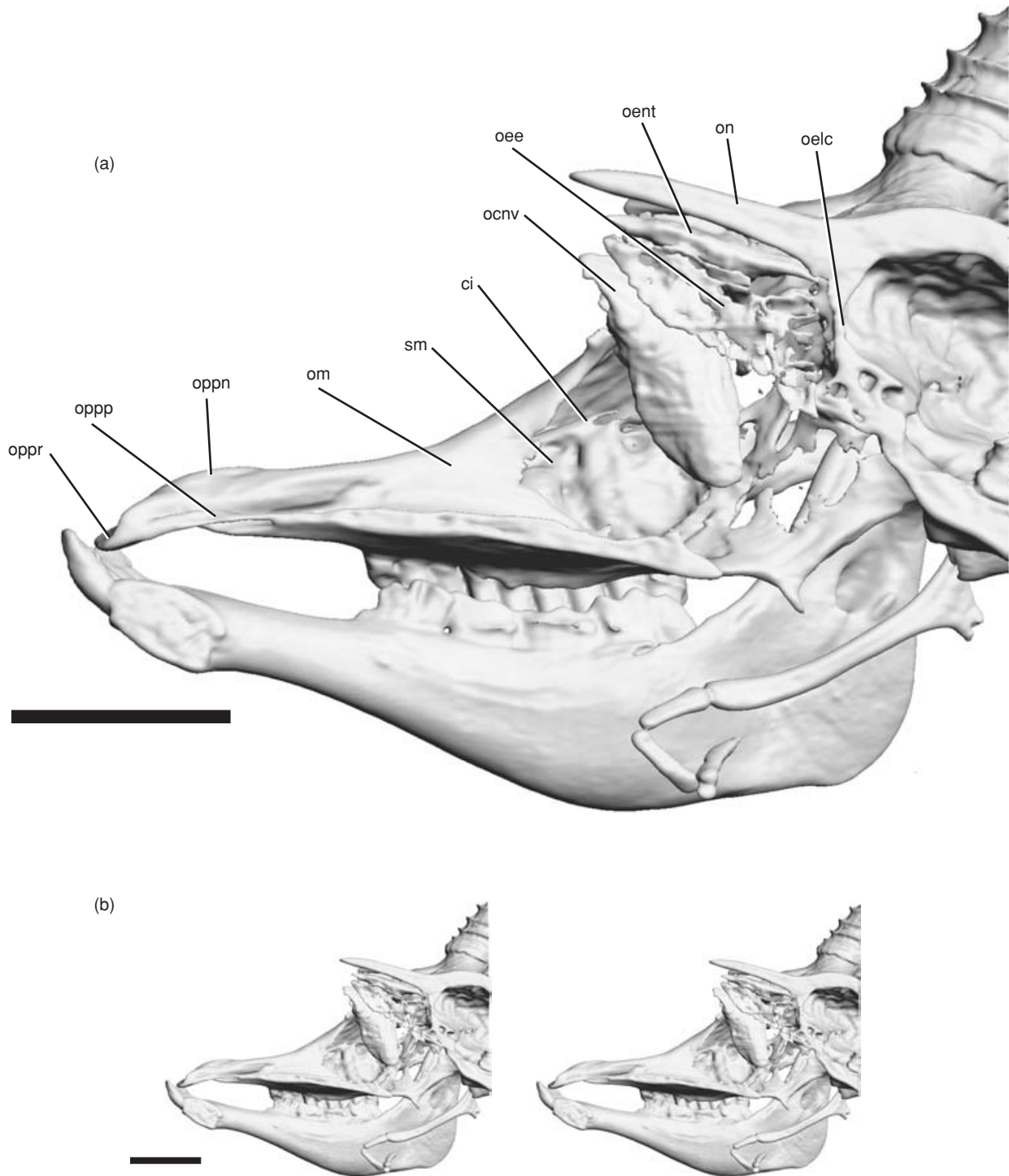


Fig. 6. Medial view of sagittally sectioned skull of *Saiga tatarica*; (a) labelled drawing of isosurface of AMNH 202492 based on 3D reconstructions of CT scans; (b) stereopairs of specimen in (a). Scale bars = 5 cm. Abbreviations as in Table 1.

to the nasolacrimal canal, a second, triangular tubercle (Fig. 5a; *olt*) serves as the attachment of the ventral lateral cartilage forming the ventral support for the nasolacrimal canal.

Os maxillare (Figs 4d-e & 6a; *om*). The maxilla forms the majority of the bony narial aperture in saiga. The shallow angle taken by the maxilla gradually increases

caudally. On the lateral surface of the maxilla between the infraorbital foramen (Fig. 5a; *omfi*) and the facial crest (Fig. 5a; *omcf*), an angled tubercle with a sharp rostral margin (Fig. 5a; *omti*) just rostral to the tuber faciale serves as the skeletal attachment of the maxillofacial muscles (i.e. the levator labii superioris, the caninus, and the depressor labii superioris). These muscles fan out along the lateral side of the proboscis, acting to compress

the nasal vestibule (Frey & Hofmann, 1995, 1997). The medial wall of the maxilla is extremely thin, as the conchae that this wall supports are reduced in saiga compared to outgroups. The basal fold takes up much of the space in the nasal cavity and has no bony skeletal support associated with it. As a result, the medial wall of the maxilla has less conchal mass to support, permitting replacement of what is bone in outgroups with a thin sheet of mucosa.

Os premaxillare. As described previously (Murie, 1870), the premaxilla is very short and shallow with a truncated nasal process (Figs 4c, 5a & 6a; *oppn*). Perhaps the most distinguishing feature of the premaxilla has remained undescribed: the rostral end of the premaxilla is curved ventrolaterally and possesses a semicircular rugose margin (Figs 4b, 5a & 6a; *oppr*). This area serves as the skeletal attachment of the incisivus superior, which itself courses rostrocaudally. The enlarged attachment site of the incisivus superior reflects its greater development in saiga. However, because the muscle's origin is ventrally displaced and its insertion is caudally displaced, the incisivus superior makes an unusual bend around the body of the premaxilla. The incisivus superior also produces a small bony lip on the medial surface of the premaxilla near the palatine process (Figs 4c & 6a; *oppp*). Thus, the larger attachment site is reflective of a larger muscle, but the incisivus superior now must travel over the dorsal surface of the body of the premaxilla before attaching to the vestibule near the ventral extent of the basal fold.

Near the shortened nasal process of the premaxilla, the lateralis nasi (transversalis nasi of Lodyshenskaya, 1952) leaves a conspicuous attachment site. This muscle is generally poorly understood in many taxa, and its enlargement probably reflects greater control of the aperture of the fleshy nostril.

DISCUSSION

Reorganization of the nasal cavity

The nasal cavity of saiga is highly divergent from the condition in ruminant outgroups. The nasal vestibule dominates the rostral half of the cavity rather than being restricted to the rostralmost portion immediately near the nostrils. The effects of this transformation have implications for many of the structures comprising the nose, particularly those interacting with the nostrils. The distal attachment sites for musculature, the ostium of the nasolacrimal duct, and the mucosal folds of the nasal cavity are all modified as a result of the caudal expansion of the vestibular portion of the nasal cavity.

The proximal attachment sites (origins) for musculature of the proboscis retain the same pattern as in outgroups, yet the distal attachments (insertions) serve externally as evidence for the caudal displacement of the nasal vestibule. For example, the levator nasolabialis retains the same origin as in many other mammals, yet its insertion has been relocated (Frey & Hofmann, 1997). Typically,

this muscle attaches on the upper lip caudal to the nostrils (Nickel, Schummer, Seiferle, Frewein *et al.*, 1986; Schaller, 1992), but its caudal retraction accompanies the caudal retraction of the vestibule. The levator nasolabialis retains an attachment approximating the extent of the nasal vestibule. However, when the vestibule is expanded as in saiga, the distal attachment of the levator nasolabialis tracks this change. The result is that the levator nasolabialis retracts the proboscis and turns the nostrils upward, creating transverse furrows in the proboscis (Frey & Hofmann, 1997). This muscle still acts upon the nasal vestibule, but its line of action has been altered.

Similarly, the maxillolabial musculature tracks the expansion of the nostril area corresponding to the nasal vestibule. Primitively, these muscles (i.e. the levator labii superioris, the caninus, and the depressor labii superioris) attach around the dorsal, caudal, and ventral portions of the nostril on the lateral wall of the nasal vestibule. These vestibular walls are retracted in saiga, and so the maxillolabial musculature attaches more dorsally than in ruminant outgroups. This relocation alters the line of action in the maxillolabial muscles from caudal retraction, as in other ruminants, to ventral compression (Frey & Hofmann, 1997). In other mammals that have well-developed musculature for compressing the nasal vestibule (e.g. hooded seals: Clifford & Witmer, 2001; moose: Clifford & Witmer, 2004), this action is carried out by *M. nasalis*. However, the dorsal lateral cartilage, which is the distal attachment for the *nasalis*, has retracted far caudally in saiga. Thus, compression of the nasal vestibule has been taken over by the maxillolabial musculature, the dorsal angulation of which makes this action possible.

The unusual morphology of the incisivus superior again reflects caudal expansion of the nasal vestibule. Primitively, this muscle attaches to ventral structures in the nasal vestibule, such as the cartilaginous septum and basal fold, and fans outward to the upper lip. Saiga control the fleshy nostril to a much larger extent than in ruminant outgroups (Frey & Hofmann, 1997), and thus its attachment to the premaxilla is much more conspicuous. The caudal relocation of the ventral attachment of the basal fold, however, has taken the musculature associated with it caudally. The incisivus superior now lies in the floor of the nasal vestibule. Thus, the ventral recess opening into the ventral nasal meatus is an epiphenomenon resulting from the caudal direction of the incisivus superior.

The nasolacrimal canal is similarly affected by the caudal relocation of the basal fold. The ostium of this canal primitively opens into the nasal cavity in the basal fold near the limen nasi (Nickel, Schummer, Seiferle & Sack, 1973), and saiga retain this condition. However, when the basal fold is retracted caudally and its dorsal termination on the alar fold is retracted dorsally and caudally, the ostium of the nasolacrimal duct accompanies this transformation. The interaction of the nasolacrimal canal with the dorsal lateral and ventral lateral nasal cartilages is most probably the result of these structures being reorganized to adjacent caudodorsal locations. Again, as a result of caudally relocating the nasal cartilages, their attachments have also travelled caudally to meet the lacrimal bone.

As bovids, saiga are constrained to having a scrolled maxilloturbinate and a series of ethmoturbinates. Rather than lose these structures, saiga modify them to accommodate the vestibular expansion. Conchae that primitively extend far rostrally into the nasal cavity are either reduced rostrocaudally (as is the straight fold) or rotated (as is the ventral concha). The retraction of the basal fold forces the turbinate-supported portion of the ventral concha into an almost vertical position. The mucosal continuation, the alar fold, is rotated around onto the nasal septum. These changes have resulted in removal of many of the conchal structures from the main airflow, such that air flowing through the nasal cavity will more likely pass over structures in the nasal vestibule and through the ventral meatus.

Proboscis function in saiga

The apomorphic nose of saiga has been implicated in a number of different functions. The mechanism of any of these functions has not been explained with reference to specific anatomical novelties, leading to some misinterpretation of the functions of anatomical novelty in saiga.

Murie (1870) regarded the proboscis of saiga as an improved tactile organ, by virtue of increased innervation and vasculature to structures comprising the proboscis. Anatomically, however, an increase in innervation or vascularity could not be verified. The infraorbital foramen does not seem to be enlarged in saiga, nor does the infraorbital nerve seem larger than in outgroups. Furthermore, the pelage covering the nose is characterized more as dense fur than as tactile vibrissae (Heptner *et al.*, 1988). The mobility of the proboscis would presumably be enhanced if tactile information from the nose was essential. The musculature of the proboscis does not contribute to enhanced movement, but rather it relates to compression of the vestibule and control of the aperture of the nostrils, limiting mobility of the vestibule as a whole. The proboscis does not extend far rostrally beyond the mouth, further limiting lateral or dorsal excursion.

It is clear in the proboscis of saiga that air inhaled into the nasal cavity will interact with the enlarged nasal vestibule at the expense of the conchal structures of the nasal cavity. Several workers (Sokolov, 1974; Heptner *et al.*, 1988; Frey & Hofmann, 1997) attributed narial specializations in saiga to an increased performance of the air-conditioning mechanisms of the nose. When air is inhaled through the nasal cavity, it must be warmed and humidified so as not to damage the sensitive exchange surfaces of the lungs. Upon exhalation, air is passed over the same surfaces to recover the heat and humidity passed to the air during inhalation. This process is dependent upon the surface area of the conchae projecting medially into the nasal cavity (Schmidt-Nielsen, Hainsworth & Murrish, 1970). Saiga, however, do not either increase the surface area available for counter-current exchange or bring those surfaces in-line with the main airflow. Thus, a counter-current exchange mechanism is clearly not being enhanced in saiga, and, if anything, is compromised by vestibular expansion.

Frey & Hofmann (1997) support a second hypothesis, originally proposed by Bannikov *et al.* (1961), which integrates behavioural observations of saiga with their apomorphic narial apparatuses. Saiga live in dusty, arid habitats and use a highly efficient mode of locomotion in which the head is held low so that cervical musculature may be recruited into forelimb movement (Heptner *et al.*, 1988). As a result, saiga are constantly inhaling air laden with dust particles (Frey & Hofmann, 1997). The mucosa of the nasal vestibule is lined extensively with seromucous glands (Murie, 1870), providing moisture and surface area for adhering suspended particulates. The musculature of the proboscis is aligned to produce forceful compression of the vestibule, thus ridding it of dust that has accumulated on the moist mucosa. Frey & Hofmann (1997) described the nasal 'sneeze' of the proboscis as a mechanism to expel these collections of dust particles from inhaled air, recruiting maxillo-labial muscles, the levator nasolabialis, and the lateralis nasi.

Our data support this hypothesis. The mechanism by which particulate matter is adhered to the mucosa of the nasal vestibule can be explained anatomically by virtue of the size and orientation of vestibular structures. Because the nostrils are the narrowest portion of the nasal cavity, as particle-laden air enters the vestibule, its speed decreases as it passes into a space with a larger cross-sectional area (Poiseuille's Law). The largest space within the vestibule is rostral to the basal fold and caudal to the nostrils, and hence air would be travelling slowest within the vestibule. As the air slows, the suspended particles would tend to precipitate out of the air and adhere to the moist mucosa of the vestibule. The dynamics of air flow within the nasal vestibule are further altered by the cavernous tissue mass on the membranous septum, the basal fold, and the lateral recess. The cavernous mass, which can change its dimensions based on relative engorgement, may function as a baffle, dynamically adjusting the flow of air beyond the moist nasal vestibule, perhaps, when engorged, directing inhaled air and the particles suspended within it, laterally to the side wall of the nasal vestibule around the ostium of the lateral recess. The basal fold similarly would assist this interruption of direct passage of air travelling from the vestibule to the pharynx. Fluid draining from the nasolacrimal canal would follow the crescentic rostral edge of the basal fold, further trapping dust suspended dust particles immediately rostral to the main nasal cavity. Despite the arid environment in which they occur, saiga probosces are better suited anatomically for cleansing inspired air, perhaps even at the expense of the water conservation functions that would normally be set up by the conchae.

Lateral recess homology and function

A functional hypothesis suggested here for the evolution of an enlarged lateral recess in the vestibule is for the production of extra seromucous secretions available for the collection of inhaled particles. This recess may

perform a similar function to that of lateral nasal glands in other mammals. The lateral nasal glands serve as a significant source of fluid available for evaporative cooling in the nasal passageways (Blatt, Taylor & Habal, 1972), and the ostium for these glands in other mammals is associated with the straight fold (Schaller, 1992). The straight fold in saiga, however, is nearly obliterated and any secretions from glands here would lie well outside the main air passage, in the space dorsal to the rotated ventral concha. These secretions would, in saiga as in their ruminant outgroups, drain onto the dorsal scroll of the ventral nasal concha. This concha is modified into a dorsoventral orientation in saiga, and lateral nasal gland secretions would be isolated from the airflow through the nasal cavity and would drain directly ventrally into the nasopharynx. The lateral recess does not seem to have musculature capable of dilating or widening it, and so this space would presumably remain outside the airflow. Nevertheless, the mucosa of the recess is morphologically indistinguishable from the mucosa lining the remainder of the nasal vestibule. The secretions produced throughout the vestibule are also produced in the lateral recess, yet the secretion produced in the recess represents an additional source as the recess is not in the main airflow. Thus, saiga have evolved a mechanism for alternative supplementary production of fluids available for collecting suspended particles in inspired air.

The homology of this recess is uncertain, as no other bovid develops a large recess in the nasal vestibule. One difficulty in assessing potential homologues of this structure is that the majority of the nasal vestibule in saiga is homologous to a very small area just inside the nostril in other ruminants. Bovids such as oxen and goats have a basal fold, but the space ventral to the basal fold is very restricted (Nickel, Schummer, Seiferle & Sack, 1973; Schaller, 1992), so a homologous recess in these ruminants does not have the space to form or have significant functional consequences. In none of these animals is a glandular ostium described, nor was one found in the specimens of *Capra* examined here. The ostia found in most other artiodactyls are those associated with the nasolacrimal duct and the lateral nasal glands. The ostium of the nasolacrimal gland and the lateral recess in saiga are on opposite sides of the basal fold. The ostium of the lateral nasal gland is always associated with the straight fold, a structure nearly obliterated in saiga. Thus, the lateral recess is most likely a neomorph of saiga, perhaps having evolved as a direct adaptation to living in dusty habitats. The only known potentially analogous structure to the lateral recess in saiga is a nasal sac in *Camelus* described by Arnautovic & Abdalla (1969). This sac is much longer than that in saiga, yet it is capable of being compressed by musculature of the nose, specifically the maxillo-labial musculature. As in saiga, the sac in camels is lined with vestibular mucosa, producing excess seromucous secretions to keep the mucosa of the nasal cavity moist (Arnautovic & Abdalla, 1969). Saiga may have evolved a convergent structure not so much to conserve water but more to use vestibular secretions to adhere particles inhaled in an arid environment.

Acknowledgements

For access to specimens, we thank R. D. MacPhee, N. Simmons, and B. J. Mader (American Museum of Natural History, New York City). For assistance with CT scanning, we thank H. D. Mayle (O'Brien Memorial Hospital, Athens, Ohio). For assistance with the figures, we thank R. C. Ridgely. For assistance with vascular injection, we thank B. L. Beatty. For help in specimen preparation, we thank T. L. Hieronymus, C. M. Holliday and M. J. Papp. Special thanks go to S. M. Reilly, A. R. Biknevicius and the EvoMorph group at Ohio University for lively discussion and advice. Funding was provided by a John Houk Memorial Research Grant to A. B. C. and by grants to L. M. W. from the Ohio University College of Osteopathic Medicine and the National Science Foundation (IBN-9601174).

REFERENCES

- Arnautovic, I. & Abdalla, O. (1969). Unusual blind sac on the face of the one-humped camel. *Acta Anat.* **73**: 272–277.
- Bannikov, A. G., Zhirnov, L. V., Lebedeva, L. S. & Fandeev, A. A. (1961). *Biology of saiga*. Moscow: Selskokhozyajstvennaya Literature Publications.
- Blatt, C. M., Taylor, R. C. & Habal, M. B. (1972). Thermal panting in dogs: the lateral nasal gland, a source of water for evaporative cooling. *Science* **177**(4051): 804–805.
- Boas, J. E. V. & Paulli, S. (1908). *The elephant's head: studies in the comparative anatomy of the organs of the head of the Indian elephant and other mammals. Part I*. Copenhagen: Folio, Gustav Fisher.
- Clifford, A. B. & Witmer, L. M. (2001). The narial anatomy of hooded seals (*Cystophora cristata*) with respect to other Carnivora. Annual Meeting of the Society of Integrative and Comparative Biology, Chicago, Illinois. *Am. Zool.* **40**(6): 976.
- Clifford, A. B. & Witmer, L. M. (2002a). Proboscis evolution in Mammalia: preliminary studies. Annual Meeting of the Society of Integrative and Comparative Biology, Anaheim, California. *Am. Zool.* **41**(6): 153.
- Clifford, A. B. & Witmer, L. M. (2002b). Not all noses are hoses: an appraisal of proboscis evolution in mammals. Annual Meeting of the Society of Vertebrate Paleontology, Norman, Oklahoma. *J. Vertebr. Paleontol.* **22**(Suppl. to 3): 66A.
- Clifford, A. B. & Witmer, L. M. (2004). Case studies in novel anatomy. 2. The enigmatic nose of moose (Artiodactyla: Cervidae: *Alces*). *J. Zool. (Lond.)* **262**: 339–360.
- Frey, R. & Hofmann, R. R. (1995). Der Kopf der Saiga-Antilope (*Saiga tatarica tatarica* Linnaeus 1766, Mammalia: Bovidae) – Ausgewählte funktionsmorphologische Aspekte. 1. Die Speicheldrüsen, die Mandibula und die Zunge. *Zool. Beitr.* **36**(2): 169–198.
- Frey, R. & Hofmann, R. R. (1997). Skull, proboscis musculature and preorbital gland in the saiga antelope and Guenther's dikdik (Mammalia, Artiodactyla, Bovidae). *Zool. Anz.* **235**: 183–199.
- Frick, C. (1937). Horned ruminants of North America. *Bull. Am. Mus. Nat. Hist.* **69**.
- Getty, R. (1975). *Sisson and Grossman's The Anatomy of the Domestic Animals. I: General, equine, ruminant*. 5th edn. Philadelphia: W. B. Saunders.
- Hassanin, A. & Douzery, E. J. P. (2003). Molecular and morphological phylogenies of Ruminantia and the alternative position of the Moschidae. *Syst. Biol.* **52**(2): 206–228.

- Heptner, G. G., Nasimovich, A. A. & Bannikow, A. G. (1988). *Mammals of the Soviet Union. I: Artiodactyla and Perissodactyla*. Washington, DC: Smithsonian Institution Libraries and the National Science Foundation.
- Jacobi, A. (1921). Die Rüsselbildung bei Säugetieren der Gegenwart und Vorzeit. *Jen. Z. Naturwiss.* **57**: 199–218.
- Lodyshenskaya, W. I. (1952). Morphology of the upper respiratory pathways of the saiga antelope (*Saiga tatarica*). *Uch. Zap. Karelo-Finsk. Univ. Petrazavodsk.* **4**: 17–41.
- Murie, J. (1870). On the saiga antelope, *Saiga tatarica* (Pall.). *Proc. Zool. Soc. Lond.* **451**: 503.
- Nickel, R., Schummer, A., Seiferle, E., Frewein, J., Wilkens, H. & Wille, K.-H. (1986). *The anatomy of the domestic animals. I: The locomotor system of the domestic mammals*. Siller, W. G. & Stokoe, W. M. (trans.). Berlin: Verlag Paul Parey.
- Nickel, R., Schummer, A., Seiferle & Sack, W. O. (1973). *The viscera of the domestic mammals*. Siller, W. G. & Stokoe, W. M. (trans.). Berlin: Verlag Paul Parey.
- Nomina Anatomica Veterinaria* (1994). Ithaca: World Association of Veterinary Anatomy.
- Nowak, R. M. (1999). *Walker's mammals of the World*. 6th edn. Baltimore: Johns Hopkins University Press.
- Paulli, S. (1900). Über die Pneumaticität des Schädels bei den Säugethieren. Eine morphologische Studie. II. Über die Morphologie des Siebbeins und die der Pneumaticität bei den Ungulaten und Probosciden. *Gegenbaurs Morphol. Jahrb.* **28**: 179–251.
- Schaller, O. (1992). *Illustrated veterinary anatomical nomenclature*. Stuttgart: Ferdinand Enke.
- Schmidt-Nielsen, K., Hainsworth, F. R. & Murrish, D. E. (1970). Counter-current heat exchange in the respiratory passages: effect on water and heat balance. *Respir. Physiol.* **9**: 263–276.
- Sokolov, V. E. (1974). *Saiga tatarica*. *Mamm. Species* **38**: 1–4.
- Vrba, E. S. & Schaller, G. B. (2000). Phylogeny of Bovidae based on behavior, glands, skulls, and postcrania. In *Antelopes, deer, and relatives*. Vrba, E. S. & Schaller, G. B. (Eds). New Haven, CT: Yale University Press.
- Witmer, L. M. (1995). The extant phylogenetic bracket and the importance of reconstructing soft tissues in fossils. In *Functional morphology in vertebrate paleontology*: 19–33. Thomason, J. J. (Ed.). New York: Cambridge University Press.
- Witmer, L. M. (2001a). A nose for all reasons. *Nat. Hist.* **110**: 64–71.
- Witmer, L. M. (2001b). Nostril position in dinosaurs and other vertebrates and its significance for nasal function. *Science* **293**: 850–853.
- Witmer, L. M., Sampson, S. D. & Solounias, N. (1999). The proboscis of tapirs (Mammalia: Perissodactyla): a case study in novel narial anatomy. *J. Zool. (Lond.)* **249**: 249–267.